

Influence of cervical canal shape on embryo transfer feasibility

Mrugacz G., Grygoruk C. *, Grusza M., Pietrzycki B., Ratomski K., Pietrewicz P.

Center for Reproductive Medicine “Bocian”, Białystok, Poland

ABSTRACT

Purpose: To investigate the impact of cervical canal shape on embryo transfers feasibility.

Materials and methods: A retrospective study on the influence of the cervical canal shape on ET complications was conducted among one thousand patients undergoing embryo transfers in the period between 01.2011- 08.2012. The patients, based on ultrasound appearance of the cervical canal, were allocated into one of the following groups: group “I” with straight cervical canal, group “J” with cervical canal bended one time, group “C” with cervical canal bended two times in the same direction and group “Z” with cervical canal bended two times in the opposite direction.

Results: Out of the one thousand cases studied, the most prevalent cervical canal shapes were type I

(440 cases) and type J (321 cases), 19% (185) of the women had a type C cervix and 5% (54) a type Z cervix. The highest rate of uncomplicated embryo transfers was noted in single bended cervical canals, 85%. Double bended cervical canals were characterized by a high rate of complications during embryo transfer reaching 80%.

Conclusions: The results of the present study indicated that the shape of cervical canal has a great influence on embryo transfer feasibility. Special attention should be given to patients with double bended cervical canal, where the rate of complication is highest.

Key words: cervical canal, embryo transfer, guiding catheter, uterine cervix

***Corresponding author:**

Cezary Grygoruk, Center for Reproductive Medicine Bocian,
26 Akademicka str, 15-267 Białystok, Poland
Tel/Fax: +48857447700;
e-mail: cezary.grygoruk@gmail.com

Received: 05.03.2013

Accepted: 24.06.2013

Progress in Health Sciences

Vol. 3(1) 2013 pp 78-82

© Medical University of Białystok, Poland

INTRODUCTION

Embryo transfer (ET) is a fundamental element of the *in-vitro* fertilization process. During ET a newly formed embryo is placed within the uterus by means of a transcervical catheter. A successful ET includes a smooth and atraumatic passage of the ET catheter through the cervix and deposition of embryos to a site in the endometrial cavity where the chance of implantation is greatest [1]. Apart from the embryo quality and operator experience, the ET catheter properties are the most important for a positive ET outcome. Many modifications have been introduced to ET catheters throughout the years, like the atraumatic bulb tip, catheter shaping ability, precurved guiding catheter, flexible inner transfer catheter with echogenic distal tip, etc. Despite many improvements, present-day ET methods still have some imperfections [2-5]. A quite common complication encountered during ET is the obstacle in passing through the cervical canal with the ET catheter. It is usually caused by unfavorable anatomical conditions including the anatomic stenosis, acute anteflexion, retroflexion of uterus. The shape of cervical canal can differ significantly between individuals.

As yet, the impact of the cervix anatomy on ET procedures has not been entirely explained. Therefore, this study was conducted in order to find out how the shape of cervical canals influences the ET feasibility.

MATERIALS AND METHODS

A retrospective study on the influence of the cervical canal shape on ET complications was conducted among one thousand patients undergoing embryo transfers in the period between 01.2011-08.2012. All couples met standard criteria for admission to IVF. The study was approved by the Local Ethics Committee. Embryo transfers were performed with the use of the catheter (Labotect, Gottingen, Germany) by a doctor specialized in reproductive medicine. A transvaginal ultrasound examination of the cervical canal was conducted using the Voluson GE E6 and RIC5-9D intravaginal probe before the ET.

Cervical canals have several distinctive shapes, because of this, certain classifications regarding the shape of cervical canals were applied in this study, including: “I” shaped – the cervical canal is straight (I on Figure 1); “J” shaped – the cervical canal bends one time (J on Figure 1); “C” shaped – the cervical canal bends at least two times in the same direction (C on Figure 1); “Z” shaped – the cervical canal bends at least two times in opposite directions (Z on Figure 1)

An ET was considered as uncomplicated when the passage of the catheter through the cervical canal was performed without application of a tenaculum and/or cervix dilation and/or usage of excessive force resulting in blood presence inside the outer sheath of the catheter. A complicated ET was when the insertion of the catheter into the uterine cavity required application of a tenaculum and/or cervix dilation and/or usage excessive force resulting in blood presence inside the outer sheath of catheter.

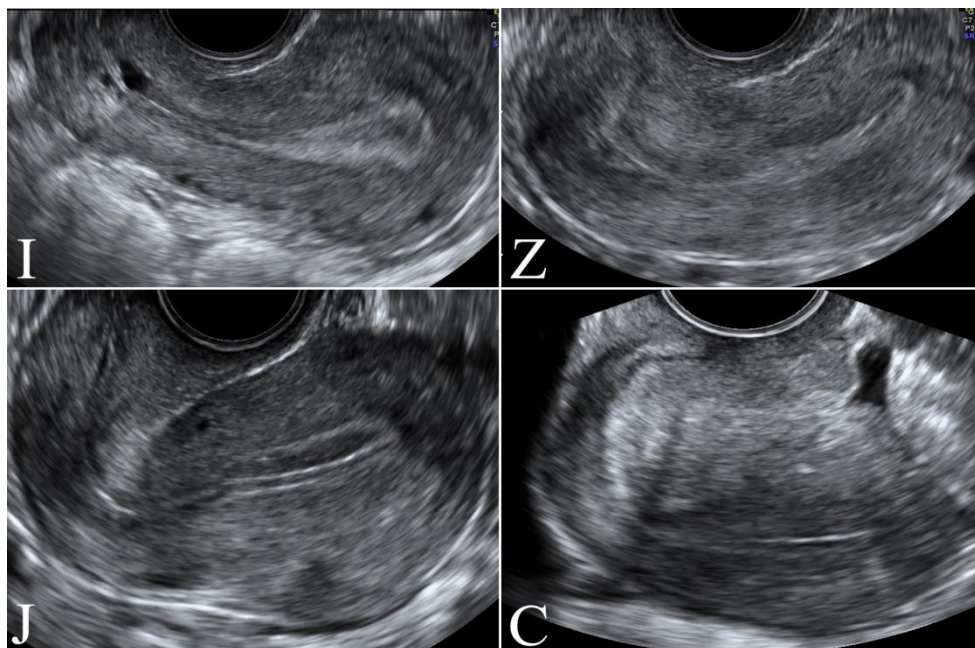


Figure 1. Most common cervical canal shapes viewed during ultrasound examination: I) type “I” – the cervical canal is straight, J) type “J” – the cervical canal bends one time, Z) type “Z” – the cervical canal bends at least two times in the opposite directions, C) type “C” – the cervical canal bends at least two times in the same direction.

Statistical Analysis

Statistical evaluation was performed using chi-square test. Differences were considered significant at $p < 0.05$. Statistical analyses were performed using the SPSS package (IBM, Chicago, USA).

RESULTS

The mean age of female patients was 32.9 ± 5.0 (SD) years, the mean duration of infertility was 3.4 ± 1.3 years. Primary infertility accounted for 100% of cases. The causes of infertility were male

factor (47%), oligo-ovulation disorders (35%), and tubal damage (18%). Infertility factors were identified in the woman alone in 29.6% of cases and the man alone in 24.2%. Two combined infertility factors were found in 16% of patients, and three combined factors in 0.2%. The rate of unexplained infertility was 18.7%.

Out of the one thousand cases studied, the most prevalent cervical canal shapes were type I (440 cases, 44%) and type J (321 cases, 32%). 19% (185) of the women had a type C cervix and 5% (54) a type Z cervix, Table 1.

Table 1. The number of uncomplicated and complicated embryo transfers in a particular type of cervical canal: "I" straight, "J" bends once, "C" bends twice in the same direction, "Z" bends twice in the opposite direction.

Cervical canal type	I	J	C	Z
No. of cases	440	321	185	54
No. of uncomplicated embryo transfers	431 (98%)*	228 (71%)*	39 (21%)	9 (17%)
No. of complicated embryo transfers	9 (2%)	93 (29%)	146 (79%)*	45 (83%)*

* $p < 0.001$

The highest rate of uncomplicated ETs was noted in the type I cervix group, 98% (431 cases). There were only nine cases (2%) of complicated ETs in this group. The difference between uncomplicated and complicated ETs was statistically significant, $p < 0.001$. The majority of ETs were uncomplicated in the type J cervix group, 228 cases (71%). Complicated ETs were encountered in 93 cases (29%) in this group, $p < 0.001$. Uncomplicated ETs constituted 21% (39 cases) and complicated ET 79% (146 cases) in the type C cervix group, $p < 0.001$. The type Z cervix group had 17% (9 cases) of uncomplicated ETs and 83% (45 cases) of complicated ETs, $p < 0.001$, (Table 1).

DISCUSSION

The aim of this study was to investigate the influence of cervical canal shape on the ET feasibility. The obtained results indicate that the highest rate of uncomplicated ETs was noted in straight and single bent cervical canals. The double bent cervical canals were characterized by a high rate of complications during ETs.

The main goal of ET is to atraumatically pass the catheter through the cervix and safely place the embryos inside the uterine cavity. Despite the relative simplicity of the procedure, clinical experience has shown that difficult ETs can occur [6]. The most common causes of complications

during ETs are cervical stenosis, acute ante flexion, retroflexion of uterus, presence of large uterine or cervical polyp or fibroid. There is a general agreement that a smooth ET is associated more frequently with a successful outcome [6-8]. On the other hand, difficult ETs have been associated with a lower pregnancy rate [9, 10]. This could be because of disruption of the endometrium, initiation of uterine contractions or the release of prostaglandins due to cervical manipulation [11].

It is known that the catheter type has a significant influence on ET complications. It was demonstrated that soft catheters had higher incidence of difficult transfers than rigid ones [6, 12]. Nevertheless, a meta-analysis of 23 randomized controlled trials revealed that softer catheters lead to a higher pregnancy rate, perhaps because of less trauma to the endometrium [12]. The catheter used in the present study was composed of two main elements, pre-curved rigid guiding catheter and soft flexible transfer catheter. The major role of the guiding catheter was to facilitate passage through the cervical canal. According to the obtained results, the guiding catheter was best suited to type I and J canals. However, the type C and Z cervical canals were associated with a considerably high rate of complications reaching up to 80%. This was caused by the inability of the guiding catheter to take on the double bended cervical canal shape. Therefore, it was necessary to adjust the cervical canal when

inserting the guiding catheter with the application of a tenaculum, dilation or excessive force resulting in bleeding from the cervical canal. The presence of blood on the tip of the catheter or bleeding at the external os is considered by some authors as a negative prognostic factor [13-16]. Furthermore, an excessive cervix manipulations has been shown to stimulate uterine contractions and increase the serum concentration of oxytocin, which may adversely affect pregnancy rate [17-19]. In order to avoid ET complications, it is very important to collect as much data as possible on cervix anatomy.

Interestingly, the present study reveals also that even experienced physician encountered obstacles during ETs in almost 30% of cases. The most plausible reason for such high rate of ET complications, is the suboptimal catheter composition. Therefore, it would be reasonable to modify or devise new catheters with a better ability to adapt to the variety of cervical canals. A major limitation in the present study has been the usage of the only one type of the ET catheter. The application of more types of ET catheters could help to address the question whether the complications during ETs were caused by anatomy of the cervix itself or the inadequate catheter design.

CONCLUSIONS

The results of the present study indicate that the shape of the cervical canal has a great influence on ET feasibility. Special attention should be given to patients with double bended cervical canals where the rate of complication is highest. The US of the cervix is an easy, quick and commonly available method of gathering information, which can be useful during ETs.

Conflicts of interest

The authors have declared no conflicts of interest.

REFERENCES

1. Tiras B, Polat M, Korucuoglu U, Zeyneloglu HB, Yarali H. Impact of embryo replacement depth on in vitro fertilization and embryo transfer outcomes. *Fertil Steril.* 2010 Sep;94(4):1341-5.
2. Grygoruk C, Pietrewicz P, Modlinski JA, Gajda B, Greda P, Grad I, Pietrzycki B, Mrugacz G. Influence of embryo transfer on embryo preimplantation development. *Fertil Steril.* 2012 Jun;97(6):1417-21.
3. Grygoruk C, Ratomski K, Kolodziejczyk M, Gagan J, Modlinski JA, Gajda B, Pietrewicz P, Mrugacz G. Fluid dynamics during embryo transfer. *Fertil Steril.* 2011 Aug;96(2):324-7.
4. Grygoruk C, Sieczynski P, Pietrewicz P, Mrugacz M, Gagan J, Mrugacz G. Pressure changes during embryo transfer. *Fertil Steril.* 2011 Feb;95(2):538-41.
5. Grygoruk C, Sieczynski P, Modlinski JA, Gajda B, Greda P, Grad I, Pietrewicz P, Mrugacz G. Influence of embryo transfer on blastocyst viability. *Fertil Steril.* 2011 Mar 15;95(4):1458-61.
6. Wood C, McMaster R, Rennie G, Trounson A, Leeton J. Factors influencing pregnancy rates following in vitro fertilization and embryo transfer. *Fertil Steril.* 1985 Feb;43(2):245-50.
7. Mansour R, Aboulghar M, Serour G. Dummy embryo transfer: a technique that minimizes the problems of embryo transfer and improves the pregnancy rate in human in vitro fertilization. *Fertil Steril.* 1990 Oct;54(4):678-81.
8. Visser DS, Fourie FL, Kruger HF. Multiple attempts at embryo transfer: effect on pregnancy outcome in an in vitro fertilization and embryo transfer program. *J Assist Reprod Genet.* 1993 Jan;10(1):37-43.
9. Sallam HN, Agameya AF, Rahman AF, Ezzeldin F, Sallam AN. Impact of technical difficulties, choice of catheter, and the presence of blood on the success of embryo transfer--experience from a single provider. *J Assist Reprod Genet.* 2003 Apr;20(4):135-42.
10. Tomas C, Tikkinen K, Tuomivaara L, Tapanainen JS, Martikainen H. The degree of difficulty of embryo transfer is an independent factor for predicting pregnancy. *Hum Reprod.* 2002 Oct;17(10):2632-5.
11. Mains L, Van Voorhis BJ. Optimizing the technique of embryo transfer. *Fertil Steril.* 2010 Aug;94(3):785-90.
12. Abou-Setta AM, Al-Inany HG, Mansour RT, Serour GI, Aboulghar MA. Soft versus firm embryo transfer catheters for assisted reproduction: a systematic review and meta-analysis. *Hum Reprod.* 2005 Nov;20(11):3114-21.
13. Alvero R, Hearn-Stokes R, Catherino W, Leondires M, Segars J. The presence of blood in the transfer catheter negatively influences outcome at embryo transfer. *Hum Reprod.* 2003;18(9):1848-52.
14. Englert Y, Puissant F, Camus M, Van Hoesck J, Leroy F. Clinical study on embryo transfer after human in vitro fertilization. *J In Vitro Fert Embryo Transf.* 1986 Aug;3(4):243-6.
15. Goudas VT, Hammitt DG, Damario MA, Session DR, Singh AP, Dumesic DA. Blood on the embryo transfer catheter is associated with decreased rates of embryo implantation and clinical pregnancy with the use of in vitro fertilization-embryo transfer. *Fertil Steril.* 1998;70(5):878-82.

16. Tiras B, Korucuoglu U, Polat M, Saltik A, Zeyneloglu HB, Yarali H. Effect of blood and mucus on the success rates of embryo transfers. *Eur J Obstet Gynecol Reprod Biol.* 2012;165(2):239-42.
17. Dorn C, Reinsberg J, Schlebusch H, Prietl G, van der Ven H, Krebs D. Serum oxytocin concentration during embryo transfer procedure. *Eur J Obstet Gynecol Reprod Biol.* 1999 Nov;87(1):77-80.
18. Lesny P, Killick SR, Robinson J, Raven G, Maguiness SD. Junctional zone contractions and embryo transfer: is it safe to use a tenaculum? *Hum Reprod.* 1999 Sep;14(9):2367-70.
19. Lesny P, Killick SR, Tetlow RL, Robinson J, Maguiness SD. Embryo transfer--can we learn anything new from the observation of junctional zone contractions? *Hum Reprod.* 1998 Jun;13(6):1540-6.