

## **Etiopathogenesis of nasal polyps**

Chojnowska S.<sup>1\*</sup>, Kęпка A.<sup>2</sup>, Waszkiewicz N.<sup>3</sup>, Kołodziejczyk ZP.<sup>4</sup>, Konarzewska-Duchnowska E.<sup>5</sup>, Ościłowicz K.<sup>4</sup>, Cabaj-Wiater I.<sup>6</sup>, Sowizdraniuk J.<sup>7</sup>, Dzieciół J.<sup>8</sup>, Ładny JR.<sup>5</sup>, Zwierz K.<sup>4</sup>, Szajda SD.<sup>5</sup>

<sup>1</sup> Medical Institute, College of Computer Science & Business Administration in Łomża, Poland

<sup>2</sup> Department of Biochemistry and Experimental Medicine, The Children's Memorial Health Institute in Warsaw, Poland

<sup>3</sup> Department of Psychiatry, Medical University of Białystok, Poland

<sup>4</sup> Medical College of the Universal Education Society, Łomża, Poland

<sup>5</sup> Department of Emergency Medicine and Disasters, Medical University of Białystok, Poland

<sup>6</sup> District Hospital of Garwolin, Poland

<sup>7</sup> Emergency Service of Krakow, Poland

<sup>8</sup> Department of Human Anatomy, Medical University of Białystok, Poland

### **ABSTRACT**

---

Nasal polyps are soft, pink or pearl white outgrowths usually connected with nasal mucosa by flaccid crus. A histological image of nasal polyps indicates significant differences in particular cases. Because of the variety of nasal polyps, the choice of proper laryngological treatment is very difficult. Difficulties in treatment are due to the lack of

consensus among physicians regarding the etiopathogenesis of nasal polyps. Probably etiopathogenesis of nasal polyps is not homogeneous and polyps' formation is influenced by many coexisting mechanisms.

**Key words:** Nasal polyps, histology, treatment

---

#### **\*Corresponding author:**

Medical Institute, College of Computer Science & Business Administration in Łomża  
14 Akademicka street, 18-400 Łomża, Poland

Tel.: +48 86 2155485

e-mail: schojnowska@pwsip.edu.pl

Received: 11.11.2013

Accepted: 28.11.2013

Progress in Health Sciences

Vol. 3(2) 2013 pp 151- 159

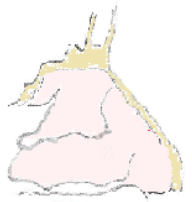
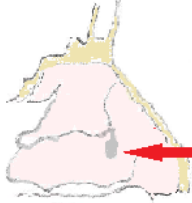
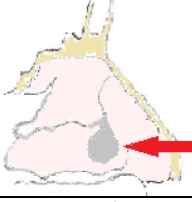
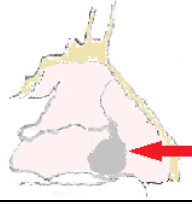
© Medical University of Białystok, Poland

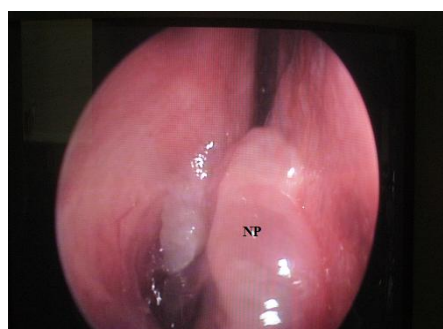
Nasal polyposis is a condition which brings physicians more questions than answers. It seems that these days it should not be an issue due to the fact that nasal polyposis affects people for centuries. Nasal polyposis was mentioned in the Hippocrates's notes from 4th century B.C. [1, 2]. Occurrence of nasal polyposis was confirmed by 3rd century B.C. inscription on the King Sabur's tombstone who had his „nostrils freed" by Egyptian physician Ni-Ankh Sekhmed [1].

Laryngologists estimate polyposis on the grounds of rhinoscopy with 4 degree scale, proposed in 1993 by Johansen [3]:

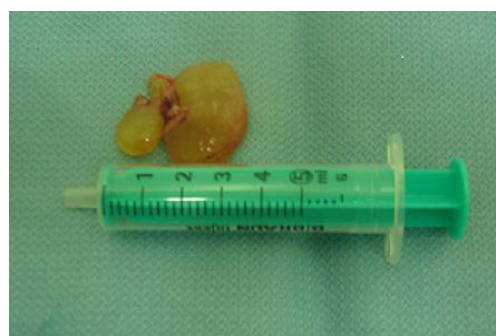Laryngologists divide nasal polyps into several types:

- unilateral,
- bilateral,
- polyps without the co-existence of chronic disorders of the respiratory system,
- those without the co-existent asthma and intolerance for non-steroidal anti-inflammatory drugs,
- with local or general immunological insufficiencies [4,5].

0°		polyps are not recognized
1°		<b>mild</b> polyposis (small polyps which do not reach upper edge of lower nasal concha)
2°		<b>moderate</b> polyposis (moderate polyps localized between upper and lower edge of lower nasal concha leading to the significant impairment of nasal cavity permeability)
3°		<b>severe</b> polyposis (leads to total occlusion of the air flow, at this part of nasal cavity)

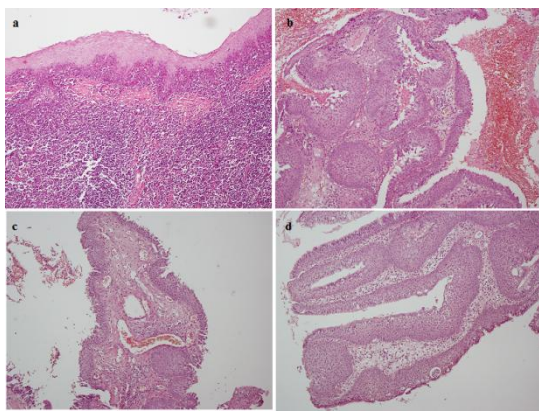


**Figure 1.** Endoscopic view of polyp in nasal cavity (NP). Picture was taken at the Department of Laryngology, Białystok Province Hospital. Authors' photo.



**Figure 2.** The polyp removed from a nasal cavity. Picture was taken at the Department of Laryngology, Białystok Province Hospital. Authors' photo.

It has to be mentioned that macroscopic image of all types of nasal polyps is similar. They are soft, pink or pearl white outgrowths, usually connected with nasal mucosa by flaccid crus (Fig. 1 and 2) [5, 6]. However, histological image reveals significant differences, in particular cases (Fig. 3). It shows that nasal polyp is covered with respiratory epithelium placed on the thickened basement membrane. The mucosa of the nasal polyp is thin. In colloid inside of the polyp, we may observe very few small vessels, seromucous glands and cellular infiltrations. In the majority of nasal polyps, eosinophilic granulocytes (eosinophiles) are present [7-9]. Eosinophilic polyps constitute 70-90% of all nasal polyps [8, 9]. Less common are neutrophilic polyps with the infiltration of neutrophil granulocytes [8, 10].



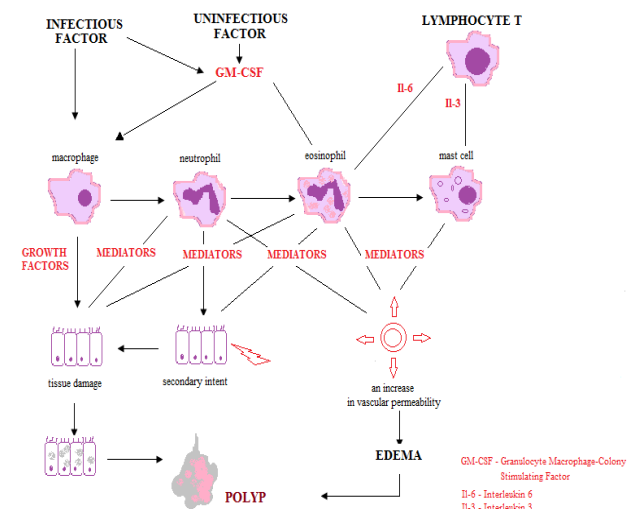
**Figure 3.** Histology of the nasal polyps. **a** – an inflammatory polyp with rich infiltration of stroma, mainly by lymphocytes (magn. 480x, HE staining), **b** – a proliferating polyp with expansion of stratified squamous epithelium (magn. 240x, HE), **c** – an inflammatory polyp with rich stromal vascularization (magn. 120x, HE), **d** – a proliferating polyp in the form of hyperplasia papillomatosis with stromal edema (magn. 240x, HE).

A histopathological examination of nasal polyps reveals many differences. The image of nasal polyps includes edemic, glandular and fibrous (also called mixed) forms [5]. Edemic forms are the majority of nasal polyps (50-60% of all cases). In such a type of the rhinal polyp's connective tissue, edema is visible along with few mixed glands covered with unaffected mucosa. Glandular form of the nasal polyps is next, according to the frequency of occurrence (27-30%). Glandular nasal polyp consists of connective tissue with edema placed centrally; large cysts and glands are visible. Mixed form of nasal polyps has its core built from fibrous connective tissue. In the core of the mixed nasal polyp, large number of infiltrations is observed (monocytes and macrophages). Such type is recognized only in 10-13% of all polypoid lesions [5].

Because of the variety of nasal polyps, the choice of proper treatment is very difficult. Only eosinophilic polyps respond to the topical treatment with glucocorticosteroids [8,11-13]. Neutrophilic polyps usually require inhalations with antibiotics [14]. Unfortunately, regardless to the type of changes, pharmacological treatment only delays the growth of nasal polyps. The long-term relief and slower regrowth may only be achieved by extensive polypectomy [11,15,16]. Difficulties in the nasal polyps' treatment are due to the lack of consensus among physicians regarding etiopathogenesis of nasal polyps.

### Etiopathogenesis of nasal polyps

Physicians agree that nasal polyps are a consequence of damage in the epithelium of the nasal mucosa. Injuries of the epithelium may be caused by bacterial or viral infection as well as prolonged inhalation of irritating substances. Damaged mucosa always tends to heal the injury through the migration of the epithelium from the edge of the damage to its inside. In some cases, a regeneration of the nasal epithelium is insufficient. A regeneration of nasal epithelium releasing cytokines, which activate inflammatory cells, may lead to the formation of nasal polyps (Fig. 4) [4].



**Figure 4.** Pathogenesis of nasal polyps (authorship own).

Different etiopathogenetic theories of nasal polyps' formation have been published.

### Polyposis as an allergic disease.

The allergic theory about nasal polyps has been presented in 1970s [17, 18]. It also appears in reports from 2011 [19]. Supporters of allergic theory claim that mucosa derived from the polyps of their patients revealed features of an allergic inflammation. An edema and eosinophil granulocytes dominated in the polypoid mucosa. Supporters of allergic theory discovered in nasal

polyps significant amounts of locally produced IgE [20]. In the smear from the nasal mucosa, the decrease in the concentration of inflammatory cells (immunocytes) has been observed after the intranasal administration of specific antigen [21]. The theory of allergic origin of nasal polyps has not been finally confirmed. The reason for doubts is connected with the fact that the percentage of patients with allergy and diagnosed nasal polyps was only 5% [4]. The patients with allergic fungal rhinosinusitis (AFRS) are the exception. In AFRS, the frequency of occurrence of nasal polyps is more than 85%. Fungal fimbriae have been observed in the para nasal sinuses of healthy patients and those with sinusitis. They probably come with inhaled air. Many authors claim that allergic reaction on fungal fimbriae occurs only in some patients. Fungal antigens act similarly to the super antigens and stimulate lymphocytes T to the production of the excessive number of cytokines, mainly interleukin 2 (IL-2). Cytokines produced by lymphocytes T provoke eosinophilic inflammations. However, there is no explanation for the excessive production of cytokines by lymphocytes T after reaction with fungal antigens [22-24]. It has to be mentioned that in patients with chronic sinusitis, reaction for fungal antigens is IgE-independent. Aforementioned facts deny the allergic theory of nasal polyp's formation.

#### **Nasal polyps as a stage of a long-term development of non-allergic rhinitis with eosinophilic syndrome.**

In 1980s, reports describing non-allergic rhinitis with the eosinophilic syndrome (NARES) appeared [25, 26]. Three stages may be differentiated in the non-allergic rhinitis. In the first-stage, eosinophiles migrate from the vessels to the nasal mucosa. In the second stage, they cumulate in the mucosa leading to the formation of nasal polyps in the third stage [26]. The weak point of the theory of non-allergic rhinitis with eosinophilic syndrome is the fact that nasal polyps have been recognized only in 30-40% of patients with NARES [27].

#### **Nasal polyps as a stage of chronic hyperplastic sinusitis development.**

Some authors claim that formation of nasal polyps occurs during chronic hyperplastic sinusitis. Chronic hyperplastic sinusitis is accompanied by large local and peripheral eosinophilosis. Chronic hyperplastic sinusitis theory is confirmed by fact that in polyp's tissue, interleukin 5 (IL-5) has been observed enabling the migration of eosinophiles to the nasal and sinus mucosa. Additionally, IL-5 is responsible for bronchial asthma in patients with chronic hyperplastic sinusitis as IL-5 leads to the accumulation of eosinophiles in pulmonary tissue [27].

Examples described above, regarding nasal polyps with eosinophilic infiltration, lead to the conclusion that polyps with neutrophils are not of allergic background and do not develop from eosinophilic inflammation.

Kim et al. [28] suggest that etiopathogenesis of eosinophilic nasal polyps may differ from etiopathogenesis of non-eosinophilic nasal polyps. They reported [28] that non-eosinophilic polyps have a thinner basement membrane than eosinophilic ones. Non-eosinophilic nasal polyps contain more lymphocytes with the expression of chemokines receptors CCR 5 and CCR 3 responsible for decreasing the number of eosinophiles in the peripheral blood of patients with non-eosinophilic nasal polyps in comparison to the eosinophilic nasal polyps [28].

#### **Nasal polyps as a stage of inflammatory-bioelectric changes development.**

In 1994, Bernstein proposed the inflammatory-bioelectric theory of nasal polyp's formation [29]. He claimed that inflammatory changes occurred as a result of turbulent air flow in the vicinity of the lateral wall of nasal cavity. Inflammations of the mucosa are exaggerated by bacterial and viral infections, which frequently bother allergic patients and those with other chronic insufficiencies of the respiratory system. Recurrent inflammatory states lead to the ulceration of mucosa and, as a consequence, to electrical changes in chloride and sodium membrane channels, according to the theory. Electrical changes in chloride and sodium membrane channels impair the secretion of chloride ions into the lumen of nasal cavity with simultaneous activation of sodium (and as a result, water) reabsorption to the inside of mucosal cells. Changes in the integrity of sodium and chloride channels lead to changes in mucus composition (it thickens) and in consequence, to difficulties in mucociliary transport. As a result of disturbances of ion channels, another portion of water penetrates interstitial tissue; – edema then occurs, and nasal polyps are formed. Other authors subsequently confirmed bioelectric theory, stating that the epithelium of nasal polyps has the capacity to extend reabsorption of Na<sup>+</sup> ions and loss of Cl<sup>-</sup> ions in comparison to the unaltered epithelium of nasal concha [30].

Bernstein's and Yankaskas's theory [31] has been developed in their further articles. They suggest that disorders in electrolytes transport in the epithelium of respiratory tract are responsible for the creation of nasal polyps. Bernstein and Yankaskas [31, 32] claim that the excessive fluid in polyps may be caused by impaired function of protein CFTR (Cystic Fibrosis Transmembrane Regulator) regulating the activity of sodium channels. Impaired CFTR protein is observed in patients with cystic fibrosis (CF) in which nasal

polyps occur very frequently (over 50% of cases) [33]. Cystic fibrosis is an inherited, autosomal recessive disorder carried by both parents who have mutated gene encoding CFTR protein. Carriers of CFTR gene do not reveal the symptoms of cystic fibrosis; however, there is lack of reports regarding the occurrence of nasal polyps in carriers of CFTR gene.

Abnormal regulation of the tissue hydration by impaired CFTR protein is connected with an increase of the number of open sodium channels on the surface of epithelium cells. Such increase on the surface of epithelium cells leads to water overflow, which causes edema of nasal polyp stroma. Furthermore, major basic protein (MBP) released by eosinophiles may be responsible for the absorption of sodium cations by the stroma. MBP decreases mucus secretion with a simultaneous increase of sodium absorption [32, 34]. Water retention in the extracellular matrix is caused by  $\text{Na}^+ - \text{K}^+$  pump which actively pumps  $\text{Na}^+$  out of cell and  $\text{K}^+$  into it against their electrochemical gradients. Sodium ions are extracellular cations, which bind water. The defective action of  $\text{Na}^+ - \text{K}^+$  pump retains  $\text{Na}^+$  in the cell instead of intercellular space [35]. Thus, accumulation of  $\text{Na}^+$  and water in the extracellular matrix of polypoid nasal mucosa cannot be explained by insufficiencies in  $\text{Na}^+ - \text{K}^+$  pump activity.

Impaired water-mineral balance may be explained by the fact that predisposition to absorb sodium and chloride ions is more developed in the epithelium of a polyp than in the epithelium of unchanged nasal conchas [30]. Main substances in intercellular space responsible for water binding are proteoglycans (proteins with long chains of chondroitin sulphate and heparan sulphate connected with polypeptide chain) and hyaluronic acid [36]. Proteoglycans and hyaluronic acid have spatially concentrated anions of sulphate groups and large amount of hydrophilic  $-\text{OH}$  groups. Only some water molecules are bound with proteoglycans through hydrogen bridges with anions and  $-\text{OH}$  groups. In the extracellular matrix of nasal polyps, the majority of water molecules are located in hyaluronian heteropolysaccharide helix [37].

Tissue of nasal polyps produces cytokines, which increase formation and growth of immunological response cells [38]. Chemokines direct cells of immunologic response to the centre of inflammation. Prostaglandins [39], as well as other mediators, are responsible for local changes. Inflammatory processes activate leukocytes (especially neutrophils) to accumulate in the center of inflammation [8, 11, 13, 15]. Accumulation of leukocytes may confirm the inflammatory background of nasal polyps. However, in polyps such symptoms as pain (*dolor*), redness (*rubor*) and increased body temperature (*calor*) are not

observed. Only edema (*tumor*) and, frequently, impairment of functions (*functio laesa*) are noted. Occurrence of eosinophils or neutrophils in nasal polyps may be connected with disorganized mechanisms leading to the full-blown inflammation.

In almost every case of intense inflammation, it can be observed the increase of glycoconjugates catabolism in lysosomes [40]. Chojnowska et al. [41, 42] recently reported a decrease of glycoconjugates metabolism in tissue of a rhinal polyp. Chojnowska et al. [41, 42] found lower concentrations and lower specific activities of lysosomal exoglycosidases in nasal polyps in comparison to hypertrophic lower nasal conchas [41,42]. Decrease of catabolism of glycoconjugates' oligosaccharide chains in polyps suggests that polyposis is not entirely an inflammatory lesion. Results of Chojnowska et al. [41, 42] may support the inflammatory-bacterial theory of nasal polyps' formation [29, 30].

Steinke et al. [43] believe that eosinophilosis observed in the majority of nasal polyps case is connected with the activity of cytokines: *IL-3*, *IL-4*, *IL-5*, *IL-13* and *CSF* released by activated lymphocytes *Th2*. Rostkowska-Nadolska [44] claims that the most important in eosinophil's activation is the *IL-4* which intensifies the migration of neutrophils to the area of chronic inflammation, inhibits their apoptosis [38] and increases the proliferation of fibroblasts and their mediators. Bachert [45] and Fan [46] prove that Interleukin 5 (*IL-5*) is crucial for migration, activation and inhibition of eosinophils in tissue. Their arguments are connected with the fact that eosinophilic granulocytes have specific receptors for Interleukin 5.

Chronic inflammation of the nasal mucosa with polyps may lead to disturbances in its immunological response. It may be assumed that nasal polyps are formed due to impaired immunological mechanisms. Hypothesis of impaired immunological mechanisms has been confirmed by Lee et al. [47] who claim that expression of 114 genes in nasal polyps is significantly different than in healthy tissue. Some of those genes have a significantly higher expression. They are connected with:

- Apoptosis,
- Cells differentiation,
- Cellular adhesion,
- Immunological response proteins,
- Extracellular matrix modification,
- Growth factors regulating cell cycle
- Immunological response proteins

According to Lee et al. [47], some genes revealed decreased expression in nasal polyps in comparison to control group. In the nasal polyps,

genes with decreased expression are coding proteins responsible for:

- Transport,
- Cell communication,
- Calcium binding,
- Proteins synthesis,
- Cytoskeleton synthesis.

Metzler et al. [48] claim that inflammatory state is the background for polyps' formation. Albumins cumulate in the subepithelial layer (in the form of cyst). It may be assumed that this effect is followed by the bioelectric changes leading to further accumulation of fluid in the extracellular matrix.

After analysis of expression of cytokines 4,13 and 19 in epithelium of nasal polyps, Rostkowska-Nadolska [44] came to a conclusion, that pathological changes in polyps regard rather stroma than epithelium. In nasal mucosa with polyps, edema of cells is not observed which leads to a conclusion that pathogenetic implications connected with cellular edema may be ignored [49].

#### **Nasal polyps as a neoplastic proliferation.**

In 2003, Fritz proposed the neoplastic theory of nasal polyps' formation. The background for neoplastic theory was the discovery of mammoglobin (glycoprotein with molecular weight 10 kD) in epithelial cells of polyps. Mammoglobin is a receptor for steroids binding which modulate inflammatory processes. Mammoglobin presence in the epithelium of polyps may explain positive influence of locally administered glucocorticoids on delaying postoperative regrowth of nasal polyps [4, 50, 51]. The presence of mammoglobin in some neoplasms (e.g. breast cancer) confirms the neoplastic theory of nasal polyps' formation. Mammoglobin is observed in lymphatic tissue of lymph nodes to which neoplasms (e.g. breast cancer) metastasize [52, 53].

In nasal polyps, gene determining the expression of glutathione transferase has also been detected. Glutathione transferase gene is assumed as a risk factor for bladder cancer [52]. It is also observed in other neoplasms, e.g., lungs, ovaries and prostate [54]. Neoplastic theory of nasal polyps was supported by de Castro [55] who reported that chemotherapeutic agent, Mitomycine C, administered locally, gives good results in nasal polyp's treatment.

One of the many factors accelerating neoplasm development are free radicals. Antioxidant barrier consists of enzymes and substrates, which remove free radicals. Olszewski et al. [56] assessed the antioxidant barrier in the serum and biopsy tissues of patients with nasal polyps. They reported significant decreases in iron, copper and zinc levels in the biopsy specimens as well as iron and copper levels in serum of patients with nasal polyps, in comparison to the control

group. According to another report of the same authors [57], decreased level of magnesium and zinc was observed in the biopsy tissues of patients with precancerous conditions in the larynx, in comparison to the healthy tissues. According to the fact that disorders in the antioxidant barrier derive from, among others, hormonal disorders, it should be considered whether nasal polyps, observed the most commonly in men, have a hormonal background.

Several reports on the activity of lysosomal exoglycosidases support the neoplastic theory of polyps' etiopathogenesis. Bosmann and Kim [58, 59] reported a lower activity of N-acetyl-beta-hexosaminidase (HEX) in colon cancer, in comparison to healthy tissue. Kim described also tendency of the activity of  $\beta$ -galactosidase,  $\beta$ -N-acetylgalactosaminidase,  $\alpha$ -mannosidase and  $\alpha$ -N-acetylgalactosaminidase in colon cancers to decrease in comparison to normal colon tissue [59]. Chojnowska et al. [4] reported significant decrease in the activity of several lysosomal exoglycosidases in nasal polyps' tissue in comparison to the activity of lysosomal exoglycosidases in hypertrophic lower nasal conchas. Borzym-Kluczyk et al. [60] reported that the activity of lysosomal exoglycosidases in the tissue of renal cancer was lower than in healthy renal tissue [41, 60].

However, in neoplastic tissues of:

- brain [40, 61],
- pancreas [62],
- larynx [40, 61],
- large intestine [63]

significant increase in the activity of lysosomal exoglycosidases has been reported.

## **CONCLUSIONS**

In conclusion, it has to be stated that review of available literature does not confirm the inflammatory theory of nasal polyp's formation. Neoplastic theory seems to be more possible. However, the strongest support has the bioelectric theory which may help to design strategy for further research on etiopathogenesis of nasal polyps focused on glycoconjugates, especially proteoglycans of connective tissue as structural elements responsible for water binding. The most probable is that the etiopathogenesis of nasal polyps is not homogeneous and nasal polyps' formation is influenced by many coexisting mechanisms [51].

### **Conflicts of interest**

The authors declared no conflicts of interest.

### **Acknowledgments**

The authors are grateful to Dr. Bogusław Łazarczyk of the Białystok Province Hospital for disclosing nasal polyps' pictures.

## REFERENCES

1. Arcimowicz M. Nasal Polyps - historical perspective. *Mag Otorynolaryngol.* 2003 Nov; 28:11-3.
2. Ślifirski JA, Parzyński S, Fal AM. Comparison of cytological evaluation of nasal polyps with postoperative histopathology. *Alergol Info.* 2008;4:120-6.
3. Johansen LV, Illum P, Kristensen S, Winther L, Petersen SV, Synnerstad B. The effect budesonide (Rhinocort) in the treatment of small and medium-size nasal polyps. *Clin Otolaryngol.* 1993;18(6): 524-7.
4. Jurkiewicz D. Nasal Polyps. *Mag Otorynolaryngol.* 2003;11 3-9.
5. Składzień J. Nasal polyps: identify and develop the basic theory of their pathogenesis. *Otolaryngol Pol.* 1999; 53(4): 441-5.
6. Ohashi Y, Nakai Y. Functional and morphological pathology of chronic sinusitis mucous membrane. *Acta Otolaryngol Suppl (Stockh).* 1983; 397:11-48.
7. Perić A, Vojvodić D, Vukomanović-Durdević B. Influence of allergy on clinical, immunological and histological characteristics of nasal polyposis. *B-ENT* 2012;8(1):25-32.
8. Wen W, Liu W, Zhang L, Bai J, Fan Y, Xia W, Luo Q, Zheng J, Wang H, Li Z, Xia J, Jiang H, Liu Z, Shi J, Li H, Xu G. Increased neutrophilia in nasal polyps reduces the response to oral corticosteroid therapy. *J Allergy Clin Immunol.* 2012 Jun; 129(6):1522-8.e5.
9. Jeong WJ, Lee CH, Cho SH, Rhee CS. Eosinophilic allergic polyp: a clinically oriented concept of nasal polyp. *Otolaryngol Head Neck Surg.* 2011 Feb; 144(2):241-6.
10. Morinaka S, Nakamura H. Inflammatory cells in nasal mucosa and nasal polyps. *Auris Nasus Larynx.* 2000 Jan; 27(1):59-64.
11. Vento S, Virkkula P. Nasal polyposis. *Duodecim.* 2012; 128(2):219-24.
12. Hamera-Słynarska M. Effects of glucocorticoids on the cytological picture of the nasal mucosa. *Mag Otorynolaryngol.* 2007; 6(2):55-8.
13. Rostkowska-Nadolska B, Mazurek U, Kapral M. Pharmacotherapy of nasal polyps. *Ann Acad Med Siles.* 2006; 60(2):163-6.
14. Jurkiewicz D. Laryngology: Disorders of the upper respiratory tract. *Nowa Klin.* 2006;1(2): 1-73.
15. Alam M, Fakir AY, Chowdhury A. A review of nasal polyposis and surgical management. *Bangladesh J Otorhinolaryngol.* 2008; 14(2):71-4.
16. Aouad RK, Chiu AG. State of the art treatment of nasal polyposis. *Am J Rhinol Allergy.* 2011 Sep-Oct; 25(5):291-8.
17. Bunnag C, Khanjanasthiti P, Dhorranintra B. The incidence of sinus involvement in allergic rhinitis Thai patients. In: Takahashi R, ed. *Proceedings of International Symposium of Infection and Allergy of the Nose and Paranasal Sinuses.* Tokyo: Scimed Publications Inc. 1976; 273-7.
18. Caplin I, Haynes JT, Spahn J. Are nasal polyps an allergic phenomenon? *Ann Allergy.* 1971 Dec; 29(12):631-4.
19. Perić A, Vojvodić D, Vukomanović-Durdević B, Baletić N. Eosinophilic inflammation in allergic rhinitis and nasal polyposis. *Arh Hig Rada Toksikol.* 2011 Dec;62(4): 341-8.
20. Donovan R, Johansson SGO, Bennich H, Soothill JF. Immunoglobulins in nasal polyp fluid. *Int Arch Allergy Appl Immunol.* 1970; 37(2):154-66.
21. Skuda H. The role of the blood basophil in allergic nasal manifestation. *Wakayama med Report.* 1979; 22:15.
22. Ponikau JU, Sherris DA, Kern EB, Homburger HA, Frigas E, Gaffey TA, Roberts GD. The diagnosis and incidence of allergic fungal sinusitis. *Mayo Clin Proc.* 1999 Sep; 74(9): 877-84.
23. Zawisza E. Fungi and allergic diseases. *Nowa Med.* 2001;109(1):11-5.
24. Gosepath J, Mann WJ. Role of fungus in eosinophilic sinusitis. *Curr Opin Otolaryngol Head Neck Surg.* 2005 Feb;13(1): 9-13.
25. Jacobs RL, Freedman PM, Boswell RN. Nonallergic rhinitis with eosinophilia (NARES syndrome). Clinical and immunologic presentation. *J. Allergy Clin Immunol.* 1981 Apr; 67(4): 53-62.
26. Mullarkey MF, Hill JS, Webb DR. Allergic and nonallergic rhinitis: their characterization with attention to the meaning of nasal eosinophilia. *J Allergy Clin Immunol.* 1980 Feb; 65(2):122-6.
27. Leone C, Teodoro C, Pelucchi A, Mastropasqua B, Cavigioli G, Marazzini L, Foresi A. Bronchial responsiveness and airway inflammation in patients with nonallergic rhinitis with eosinophilia syndrome. *J Allergy Clin Immunol.* 1997 Dec; 100(6 Pt 1):775-80.
28. Kim JW, Hong SL, Kim YK, Lee CH, Min YG, Rhee CS. Histological and immunological features of non-eosinophilic nasal polyps. *Otolaryngol Head Neck Surg.* 2007 Dec; 137(6):925-30.
29. Bernstein JM, Gorfien J, Noble B. Role of allergy in nasal polyposis. *Otolaryngol Head Neck Surg.* 1995 Dec; 113(6):724-32.
30. Al-Bazzaz F, Yadava VP, Westenfelder C. Modification of Na<sup>+</sup> and Cl<sup>-</sup> transport in canine tracheal mucosa by prostaglandins. *Am J Physiol.* 1981 Feb;240(2):F101-5.
31. Bernstein JM, Yankaskas JR. Increased ion transport in cultured nasal polyp epithelial cells. *Arch Otolaryngol Head Neck Surg.* 1994 Sep; 120(9):993-6.

32. Bernstein JM. Update on the molecular biology of nasal polyposis. *Otolaryngol Clin North Am*. 2005 Dec;38(6):1243-55.
33. Mainz JG, Koitschev A. Pathogenesis and management of nasal polyposis in cystic fibrosis. *Curr Allergy Asthma Rep*. 2012 Apr; 12(2): 163-74.
34. Bernstein JM; Kansal R: Super antigen hypothesis for the early development of chronic hyperplastic sinusitis with massive nasal polyposis. *Curr Opin Otolaryngol Head Neck Surg*. 2005 Feb; 13(1):39-44.
35. Zwierz K, Wielgat P, Borzym-Kluczyk M. Molecular mechanisms regulating transport of low molecular weight substances in the hepatocyte. *Postepy Hig Med Dosw*. 2003; 57(1):91-116.
36. Sadowski M, Borzym-Kluczyk M, Stypułkowska A, Wielgat P, Zwierz K. The extra cellular matrix of the vein wall. *Prz Fleobol*. 2006; 14(4):141-9.
37. Hardingham TE, Perkins SJ, Muir H. Molecular conformations in proteoglycan aggregation. *Biochem Soc Trans*. 1983 Apr;11(2):128-30.
38. Rostkowska-Nadolska B, Pośpiech L, Preś K. The role of cytokines in nasal polyps. *Otolaryngologia* 2006;5(1):1-6.
39. Kawano M, Okada K, Muramoto H, Morishita H, Omura T, Inoue R, Kitajima S, Katano K, Koni I, Mabuchi H, Yachie A. Simultaneous, clonally identical T cell expansion in tonsil and synovium in a patient with rheumatoid arthritis and chronic tonsillitis. *Arthritis Rheum*. 2003 Sep;48(9):2483-8.
40. Chojnowska S, Kęпка A, Szajda SD, Waszkiewicz N, Bierć M, Zwierz K. Exoglycosidase markers of diseases. *Biochem Soc Trans*. 2011 Jan;39(1):406-9.
41. Chojnowska S, Minarowska A, Knaś M, Niemcunowicz-Janica A, Kołodziejczyk P, Zalewska-Szajda B, Kęпка A, Minarowski Ł, Waszkiewicz N, Zwierz K, Ładny JR, Szajda SD. Lysosomal exoglycosidases in nasal polyps. *Otolaryngol Pol*. 2013 Jul-Aug;67(4):192-7.
42. Kęпка A, Szajda SD, Jankowska A, Waszkiewicz N, Chojnowska S, Zwierz K. N-acetyl-beta-hexosaminidase--marker of damage to renal proximal tubules. *Pol Merkur Lekarski* 2008 Sep;25(147):288-90.
43. Steinke JW, Crouse CD, Bradley D, Hise K, Lynch K, Kountakis SE, Borish L. Characterization of interleukin-4-stimulated nasal polyp fibroblasts. *Am J Respir Cell Mol Biol*. 2004 Feb;30(2):212-9.
44. Rostkowska-Nadolska B, Jaworska M, Kubacka M, Bochnia M. Expression of cytokeratin 4, 13, 19 in nasal polyps epithelium. *Adv Clin Exp Med*. 2005;14(5):891-5.
45. Bachert C, Gevaert P, Holtappels G, van Cauwenberge P. Mediators in nasal polyposis. *Curr Allergy Asthma Rep*. 2002 Nov; 2(6): 481-7.
46. Fan GK, Wang H, Takenaka H. Eosinophil infiltration and activation in nasal polyposis. *Acta Otolaryngol*. 2007 May;127(5): 521-6.
47. Lee JY, Lee SH, Lee HM, Lee SH, Jung HH, Lee SW, Kang SM. Analysis of gene expression profiles of normal human nasal mucosa and nasal polyp tissues by SAGE. *J Allergy Clin Immunol*. 2006 Jul; 18(1):134-42.
48. Meltzer EO, Hamilos DL, Hadley JA, Lanza DC, Marple BF, Nicklas RA, Bachert C, Baraniuk J, Baroody FM, Benninger MS, Brook I, Chowdhury BA, Druce HM, Durham S, Ferguson B, Gwaltney JM, Kaliner M, Kennedy DW, Lund V, Naclerio R, Pawankar R, Piccirillo JF, Rohane P, Simon R, Slavin RG, Togias A, Wald ER, Zinreich SJ. Rhinosinusitis: Establishing definitions for clinical research and patient care. *Otolaryngol Head Neck Surg*. 2004 Dec; 131(6 Suppl):1-62.
49. Hellquist HB. Histopathology of nasal polyps. In: Settupane GA, Lund VJ, Bernstein JM, Tos M (eds): *Nasal polyps, epidemiology, pathogenesis and treatment*. Ocean Side Providence. 1997: 31-19.
50. Granstrom G, Jacobsson E, Jeppsson PH. Influence of allergy, asthma and hypertension on nasal polyposis. *Acta Otolaryngol Suppl*. 1992; 492: 22-7.
51. Arcimowicz M, Balcerzak J, Samoliński BK. Nasal polyps is not a homogenous pathology. *Pol Merkur Lekarski*. 2005 Sep;19(111):276-9.
52. Yan Z, Gidley J, Horton D, Roberson J, Eltoum IE, Chheng DC. Diagnostic utility of mammaglobin and GCDFP-15 in the identification of metastatic breast carcinoma in fluid specimens. *Diagn Cytopathol*. 2009 Jul; 37(7):475-8.
53. Bernstein JL, Godbold JH, Raptis G, Watson MA, Levinson B, Aaronson SA, Fleming TP. Identification of mammaglobin as a novel serum marker for breast cancer. *Clin Cancer Res*. 2005 Sep 15; 1(18):6528-35.
54. Bhargava R, Beriwal S, Dabbs DJ. Mammaglobin vs GCDFP-15: an immunohistologic validation survey for sensitivity and specificity. *Am J Clin Pathol*. 2007 Jan; 127(1):103-13.
55. De Castro MC, Assuncao E, De Castro MM, Araujo RN, Guimaraes RE, Nunes FB. Effect of mitomycin C in eosinophilic nasal polyposis, in vivo: concentration of IL5 and GM-CSF, RT-PCR. *Braz J Otorhinolaryngol*. 2006 Jan-Feb; 72(1):38-42.
56. Olszewski J, Starostecka B, Latusiński J, Kita A, Starnawski M. Assessment of antioxidative element concentrations in blood serum and tissue bioplates in patients with nasal polyps. *Otolaryngologia*. 2003; 2(4):189-91.



57. Olszewski J, Latusiński J, Kita A. Comparative assessment of antioxidative elements concentration in blood serum and tissue bioptates from patients with papilloma or cancer of larynx. *Otolaryngologia* 2003; 2(2):90-3.
58. Bosmann HB, Hall TC. Enzyme activity in invasive tumors of human breast and colon. *Proc Natl Acad Sci USA*. 1974 May; 71(5): 1833-7.
59. Kim YS, Isaacs R. Glycoprotein metabolism in inflammatory and neoplastic diseases of the human colon. *Cancer Res*. 1975 Aug; 35(8): 2092-7.
60. Borzym-Kluczyk M, Radziejewska I, Olszewska E, Szajda S, Knaś M, Zwierz K. Statistical evaluation of the isoform patterns of N-acetyl-beta-hexosaminidase from human renal cancer tissue separated by isoelectro-focusing. *Clin Biochem*. 2007 Mar; 40(5-6): 403-6.
61. Choromańska B, Luto M, Szajda SD, Waszkiewicz N, Kęпка A, Janica J, Ladny JR, Dadan J, Myśliwiec P, Zwierz K. Activity of N-acetyl- $\beta$ -hexosaminidase and its isoenzymes A and B in cancer. *Postepy Hig Med Dosw. (Online)*. 2011 Nov 23; 65:752-8.
62. Szajda SD, Waszkiewicz N, Chojnowska S, Zwierz K. Carbohydrate markers of pancreatic cancer. *Biochem Soc Trans*. 2011 Jan; 39(1): 340-3.
63. Szajda SD, Borzym-Kluczyk M, Snarska J, Puchalski Z, Zwierz K. N-acetyl-beta-D-hexosaminidase and its isoenzymes A and B in blood serum and urine, as a potential colon cancer markers. *Hepatogastroenterology*. 2009 Sep-Oct; 56(94):1287-98.